
Brief communication

Sonographic screening for urinary tract abnormalities in patients with *Schistosoma haematobium* infection: pitfalls in examining pregnant women

J. Richter,¹ Y. Wagatsuma,² M. Aryeetey,³ & H. Feldmeier⁴

In areas where Schistosoma haematobium is endemic, urinary schistosomiasis and pregnancy are frequently concomitant; however, both these conditions may produce similar urinary tract changes in ultrasound scans and hence their differential diagnosis may be difficult. In patients with urinary schistosomiasis, focal and/or diffuse urinary bladder wall changes are frequently detected ultrasonically. Dilatation of one or both ureters and progressive hydronephrosis may be observed in more severe cases. Satisfactory ultrasound examination of the urinary bladders of pregnant women is generally not feasible because mechanical compression by the fetus or transitory lower urinary tract infection hampers adequate filling of the bladder. Pregnancy itself is frequently associated with dilatation of one or both ureters and/or hydronephrosis; this is due to hormonal factors, infection, or compression of one or both ureters by the enlarged uterus and growing fetus. Hence, when sonography of the urinary bladder is not feasible such pregnancy-associated changes are virtually indistinguishable from those caused by S. haematobium, and may be incorrectly attributed to the latter. Pregnant women, therefore, should be excluded from ultrasonic surveys of urinary schistosomiasis. In contrast, ultrasound scans of adolescents and of women with positive parasitological findings and/or pathological alterations in the urinary tract should include examination of the uterus in order to assess whether the woman is pregnant; thereby, misinterpretation of sonographic findings can be avoided. Pregnant women with significant hydronephrosis must be closely followed up by an obstetrician since this condition may indicate a complication of the pregnancy; in some cases only a postpartum examination will permit definitive diagnosis.

Introduction

The value of ultrasound in diagnosing urinary schistosomiasis is generally accepted. Detectable alterations include those of the fibrotic bladder wall and dilatation of the upper urinary tract (1-6). A workshop to develop guidelines for the standardization of the ultrasound findings in patients with urinary schistosomiasis was convened by WHO in order to facilitate international comparison of morbidity data. However, in the proposed stan-

darized protocol the particular diagnostic problems encountered with pregnant women are not considered and the examination of the uterus is not included (7).

Urinary tract alterations, e.g., dilatation of the ureters and renal pelvis, frequently occur in pregnant women (8-11). Such alterations can be caused by physiological gestation hormones, leading to "tonogenic dilatation" of the ureter and/or by mechanical compression of one or both ureters by the enlarged uterus and the growing fetus; they can also be associated with pathological conditions, e.g., urinary tract infections, which occur frequently during pregnancy (11, 12). Such alterations are detectable by ultrasound scan from the 6th week of gestation. In Africa, women have an average of 6.5 children and adolescent pregnancies are common (13). Therefore, urinary tract alterations associated with pregnancy should be borne in mind when interpreting the results of ultrasound screening in areas where *Schistosoma haematobium* is endemic.

¹ Staff Physician, Institut für Tropenmedizin, Engeldamm 62, 10179 Berlin, Germany. Requests for reprints should be sent to this author.

² Japan International Cooperation Agency Expert on Schistosomiasis, Noguchi Memorial Institute for Medical Research, Legon, Ghana.

³ Research Fellow, Parasitology Unit, Noguchi Memorial Institute for Medical Research, Legon, Ghana.

⁴ Senior Lecturer, Institut für Tropenmedizin, Berlin, Germany.

Reprint No. 5694

Materials and methods

In July and August 1993 we carried out a survey of urinary schistosomiasis in the Accra region of southern Ghana as part of a research project on schistosomiasis control. The survey was conducted cooperatively between Noguchi Memorial Institute for Medical Research, the University of Ghana, and the Japan International Cooperation Agency. After obtaining their informed individual consent (in the case of children also that of their parents), 174 patients with parasitologically proved urinary schistosomiasis, 73 of whom were female (median age: 17 years; range: 6–61 years) were included (14). A total of 34 women were of childbearing age. Five of the women (age range: 17–38 years) were pregnant (gestational age: 4–34 weeks).

Samples of patients' urine were collected between 10:00 and 14:00 and examined by syringe nucleopore filtration (15). Microhaematuria and proteinuria levels were assessed using test strips (15).

For ultrasound examinations a portable general purpose ultrasound scanner that conformed to WHO specifications (Aloka model SSD-500; Aloka, Tokyo, Japan) with a convex 3.5 MHz transducer connected to a portable generator (Honda, Tokyo, Japan) was used (16). Photodocumentation was carried out using an echocopier (Aloka model SSZ-305; Aloka, Tokyo, Japan) on printing paper (Sony type II, Sony Corporation, Tokyo, Japan). Complete

abdominal ultrasound examinations were carried out following WHO guidelines, as revised by Hatz et al. (7). When signs of urinary tract dilatation were encountered, the findings were checked after the cases had emptied their bladders (17). The uteri of all women of childbearing age were systematically screened for signs of pregnancy.

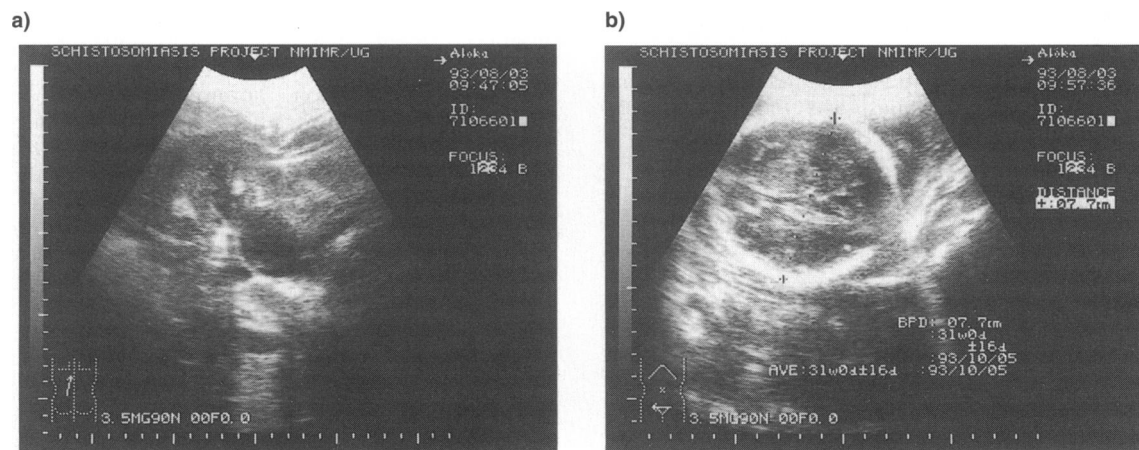
Statistical analyses were carried out using Fisher's exact test and the Mantel-Haenzel test.

Results

Parasitological examinations

The parasitological examinations revealed egg counts of 9–221 ova per 10ml urine (geometric mean, 47.94 ova per 10ml) among the five pregnant women and 1–6454 ova per 10ml among non-pregnant women (geometric mean, 64.72 ova per ml). Among the five women who were pregnant macrohaematuria was observed in three (60%), microhaematuria in all, and proteinuria in four (80%). Macrohaematuria was present in 19 of the 68 nonpregnant women, and in 4 (80%) of the pregnant women. Of the 68 nonpregnant women, 19 (27.9%) had macrohaematuria, 59 (86.7%) had microhaematuria, and 53 (77.9%) had proteinuria. There were no significant differences in these parameters between pregnant and nonpregnant women or between men and women.

Fig. 1. Ultrasound scans of a Ghanaian woman in week 32 of pregnancy a) Dorsal longitudinal scan of the left ureter and kidney, revealing dilatation of the ureter and renal pelvis. b) Transverse scan of the inferior abdomen: fetal skull (the line between the crosses indicates the biparietal diameter). Urine filtration revealed 9 *Schistosoma haematobium* ova per 10ml. Macrohaematuria was present and the reagent test strip was positive for haematuria and proteinuria (leukocyturia was not assessed). The woman did not succeed in retaining enough urine for adequate ultrasound examination to be made of her bladder; it was therefore not possible to determine the cause of the bilateral ureter dilatation and hydronephrosis.



Ultrasound findings

Nonpregnant women with urinary schistosomiasis. Urinary bladder. Schistosomiasis was responsible for bladder wall irregularities in 30, focal irregularities in 23, and diffuse bladder wall thickening in 5 of the 68 women in this category; intraluminal masses occurred in 2 of these women and polyps in 1 of them.

Ureters. Dilatation of one or both ureters at the renal end, the ostium, both extremities, or entirely was detectable by ultrasound in 6/68 patients.

Kidneys. Dilatation of the renal pelvis (from fissure to moderate degree) was observed in 5/68 cases. Abnormality of the ureters and/or the kidneys was always associated with bladder wall alterations.

Pregnant women with urinary schistosomiasis. Urinary bladder. Three women in the second and third trimesters had difficulties in retaining enough urine for a reliable examination to be performed. Thus, no information on bladder wall alterations could be obtained. Two patients in the fourth and eighth weeks of pregnancy succeeded in adequately filling their bladders. Ultrasound scans revealed no bladder abnormalities in these cases.

Ureters. Bilateral dilatation above the pelvic brim was found in one of the five pregnant women.

Kidneys. There were three cases of mono- or bilateral fissures of the renal pelvis, while moderate hydronephrosis, which was associated with ureteral dilatation, was observed in one case (Fig. 1).

Discussion

In the course of a parasitological and sonographical survey for urinary schistosomiasis in an endemic region of Ghana, we found urinary tract alterations among *S. haematobium*-infected pregnant women. Some sonographic finding related to *S. haematobium* infection, i.e., upper urinary tract dilatation, resembled those commonly found during pregnancy, and thus made causal interpretation difficult. As a result, we compared the ultrasound findings for *S. haematobium*-infected pregnant and nonpregnant women with those that commonly occur in pregnant women outside endemic areas (8, 9, 12).

The sonographic alterations detected in patients with urinary schistosomiasis corresponded uniformly to those described in the literature (1-6). The abnormalities encountered among pregnant women with concomitant *S. haematobium* infections were, on the whole, indistinguishable from those that occur during pregnancy alone (8, 9, 12). This was due to the inability of women at the more advanced stages

of pregnancy to fill adequately their bladders. Thus the full extent of bladder alterations caused by schistosomiasis could not be assessed.

Upper urinary tract dilatation cannot be regarded as being specific of pregnancy or of urinary schistosomiasis, since it occurs as a symptom of many other diseases that hamper the flow of urine, e.g., urolithiasis, as well as in nonspecific or specific bacterial urinary tract infection (11, 12, 18-20). In such cases even parasitological or biochemical investigations are of little further assistance; for example, it does not follow that urinary tract abnormalities detected ultrasonically in a woman with *S. haematobium* eggs in her urine, with or without proteinuria, leukocyturia and microhaematuria, are due to schistosomiasis, since they could also be caused by pregnancy or a pregnancy-related urinary infection. Differential diagnosis of urinary tract abnormalities in pregnant women is therefore frequently not feasible. In certain cases, various criteria may help to assess whether upper urinary tract dilatation is due to pregnancy or schistosomiasis. First, if a pregnant woman who presents with hydronephrosis can achieve adequate bladder filling (e.g., in the first trimester), total lack of or relatively mild urinary bladder abnormalities suggest that the hydronephrosis is related to pregnancy. Second, dilatation of the ureter and renal pelvis associated with pregnancy occurs more frequently on the right side than on the left, and if it occurs bilaterally stasis is more prominent on the right side (8, 9). Third, ureteral dilatation in pregnant women always begins above the pelvic brim, whereas that caused by urinary schistosomiasis commonly originates near the ureteral orifice (8, 9). Fourth, upper urinary tract dilatation during early pregnancy is fairly moderate; more severe dilatation has been reported after the first trimester only (8, 9).

In some cases definite diagnosis may be achieved sonographically only after delivery. Major urinary tract dilation arising from pregnancy usually regresses within 48 hours of delivery. Persistence of minor dilatation of the renal pelvis up to 12 weeks' postpartum has been reported in individual cases (9, 10). A slight anechoic fissure in the renal pelvis should not be considered pathological in women because this may persist also after the 12th week postpartum, especially in pluriparae (9, 10).

In conclusion, data from pregnant women obtained through ultrasound surveys of urinary schistosomiasis, should be considered separately. Ultrasound scans of adolescents and women with positive parasitological findings and/or pathological alterations of the urinary tract should include examination of the uterus in order to assess whether the woman is pregnant; thereby, misinterpretation of

sonographic findings can be avoided. Furthermore, when an ultrasound scan reveals that a woman is pregnant, treatment may be deferred (15). Occurrence of major upper urinary tract dilatation in a pregnant woman indicates that she may have pathological conditions that are causing complications in the pregnancy.

Acknowledgements

The study was part of a survey funded by Japan International Cooperation Agency (JICA) and Noguchi Memorial Institute for Medical Research (NMIMR). We thank Professor F. Nkrumah for valuable advice and the JICA and NMIMR teams for their collaboration. Dr E. Kjetland and Mrs F. Warneck are thanked for revising the English content of the article.

Résumé

Dépistage échographique des anomalies des voies urinaires chez les patients présentant une infection à *Schistosoma haematobium*: pièges à éviter chez la femme enceinte

Dans les régions d'endémie de *Schistosoma haematobium*, il n'est pas rare de rencontrer des femmes enceintes atteintes de bilharziose; cependant, la grossesse comme la bilharziose peuvent induire des modifications analogues des voies urinaires visibles à l'échographie et poser des problèmes de diagnostic différentiel. Chez les patients atteints de schistosomiase urinaire, des altérations focales et/ou diffuses de la paroi vésicale sont fréquemment visibles à l'échographie. Dans les cas graves, on peut observer une dilatation de l'un ou des deux uretères, souvent associée à une hydronéphrose évolutive. Il est en général impossible de procéder de façon satisfaisante à l'échographie de la vessie chez la femme enceinte, parce que la compression mécanique exercée par le fœtus ou une infection transitoire des voies urinaires basses l'empêchent de se remplir correctement. La grossesse en elle-même est fréquemment associée à une dilatation de l'un ou des deux uretères et/ou à une hydronéphrose; ce peut être dû à des facteurs hormonaux, à une infection, ou à la compression de l'un ou des deux uretères par l'utérus gravide. C'est pourquoi, lorsque l'échographie vésicale n'est pas réalisable, ces modifications associées à la grossesse sont pratiquement impossibles à distinguer de celles causées par *S. haematobium* et peuvent être attribuées à tort à ce

dernier. Il faut donc exclure les femmes enceintes des enquêtes échographiques sur la bilharziose urinaire. En revanche, l'analyse échographique des adolescentes et des femmes présentant des résultats parasitologiques positifs et/ou des altérations pathologiques des voies urinaires doit comprendre l'examen de l'utérus, de façon à repérer une éventuelle grossesse; ainsi, on évitera les erreurs d'interprétation des résultats échographiques. Les femmes enceintes présentant une hydronéphrose importante doivent faire l'objet d'une surveillance étroite de la part de l'obstétricien, car ce peut être le signe d'une complication de la grossesse; dans certains cas, seul un examen effectué après l'accouchement permettra de poser un diagnostic définitif.

References

1. Degrémont A et al. Value of ultrasonography in investigating morbidity due to *Schistosoma haematobium* infection. *Lancet*, 1985, **1**: 662–665.
2. Burki A et al. Comparison of ultrasonography, intravenous pyelography and cystoscopy in detection of urinary tract lesions due to *Schistosoma haematobium*. *Acta tropica*, 1986, **43**: 139–151.
3. Heurtier Y et al. Urinary tract lesions due to *Schistosoma haematobium* infection assessed by ultrasonography in a community-based study in Niger. *American journal of tropical medicine and hygiene*, 1986, **35**: 1163–1172.
4. Dittich M, Doehring E. Ultrasonographical aspects of urinary schistosomiasis: assessment of morphological lesions in the upper and lower urinary tract. *Pediatric radiology*, 1986, **16**: 225–230.
5. Lamothe F et al. L'échographie dans la bilharziose urinaire. A propos de 304 examens pratiqués au Niger. *Annales de radiologie*, 1988, **31**: 297–300.
6. Hatz C et al. Ultrasound for detection of morbidity due to *Schistosoma haematobium* and its resolution following treatment with different doses of praziquantel. *Transactions of the Royal Society of Tropical Medicine and Hygiene*, 1990, **84**: 84–88.
7. Hatz C, Jenkins JM, eds. The use of diagnostic ultrasound in schistosomiasis — attempts at standardization of methodology by the Cairo Working Group. *Acta tropica*, 1992, **51**: 45–63.
8. Schmoller H. [Ultrasound investigation of the kidneys during pregnancy]. *Röntgenpraxis*, 1982, **35**: 69–73 (in German).
9. Cietak KA, Newton JR. Serial qualitative maternal nephrosonography in pregnancy. *British journal of radiology*, 1985, **58**: 399–404.
10. Hibbard BM. *Principles of obstetrics*. London, Butterworth & Co., 1988: 325–336.
11. Finas B et al. Conduite à tenir devant les images hyperéchogènes multiples limitées du rein. *Échographie*, 1988, **11**: 28–31.

Sonographic screening for *Schistosoma haematobium* infection

12. **Buchsbaum HJ, Schmidt JD**, eds. *Gynecologic and obstetric urology*, 3rd ed. Philadelphia, PA, Saunders, 1993: 581–585.
13. **Royston E, Armstrong S**. *Preventing maternal deaths*. Geneva, World Health Organization, 1989: 45–49.
14. **Ijsselmuiden CB, Faden RR**. Research and informed consent in Africa — another look. *New England journal of medicine*, 1992, **326**: 830–834.
15. *The control of schistosomiasis. Second Report of the WHO Expert Committee*. Geneva, Switzerland, 1993: 56–59 (WHO Technical Report Series No. 830).
16. *Future use of new imaging technologies in developing countries*. Geneva, Switzerland, 1985 (WHO Technical Report Series No. 723).
17. **Morin ME, Baker D**. The influence of hydration and bladder distension on the sonographic diagnosis of hydronephrosis. *Journal of clinical ultrasound*, 1979, **7**: 192–194.
18. **Ellenbogen PH et al**. Sensitivity of gray scale ultrasound in detecting urinary tract obstruction. *American journal of roentgenology*, 1978, **130**: 731–733.
19. **Boyarsky S et al**. Aperistaltic ureter in upper urinary tract infection — cause or effect? *Urology*, 1978, **12**(2): 134–138.
20. **Lagalla R et al**. Aspects échographiques de la tuberculose rénale. *Échorevue*, 1989, **12**: 100–107.